

Laceration Zones

- Consider ending bout**
 - Careful evaluation of depth
 - One – tarsal plate, lacrimal sac**
 - Two - vermilion border**
 - Three – supraorbital / supratrochlear nerves
 - Four – nasal bridge, **FRACTURE**
 - Five – infraorbital nerve
 - Six – nasolabial fold with facial artery
 - Seven — superficial temporal artery, facial nerve (at the zygomatic bone)
 - Eight - facial artery at masseter**
 - Nine – mental nerve**
-
- Image by Karl Weskar modified from Gilroy (et al. Theme Atlas of Anatomy)

Larry Lovelace, DO, FACEP & Daniel O'Donoghue, PA-C, PhD

Laceration Zones

- Consider ending bout**
 - Careful evaluation of depth
 - One – tarsal plate, lacrimal sac**
 - Two - vermilion border**
 - Three – supraorbital / supratrochlear nerves
 - Four – nasal bridge, **FRACTURE**
 - Five – infraorbital nerve
 - Six – nasolabial fold with facial artery
 - Seven — superficial temporal artery, facial nerve (at the zygomatic bone)
 - Eight - facial artery at masseter**
 - Nine – mental nerve**
-
- Image by Karl Weskar modified from Gilroy (et al. Theme Atlas of Anatomy)

Larry Lovelace, DO, FACEP & Daniel O'Donoghue, PA-C, PhD

Laceration Zones

- Consider ending bout**
 - Careful evaluation of depth
 - One – tarsal plate, lacrimal sac**
 - Two - vermilion border**
 - Three – supraorbital / supratrochlear nerves
 - Four – nasal bridge, **FRACTURE**
 - Five – infraorbital nerve
 - Six – nasolabial fold with facial artery
 - Seven — superficial temporal artery, facial nerve (at the zygomatic bone)
 - Eight - facial artery at masseter**
 - Nine – mental nerve**
-
- Image by Karl Weskar modified from Gilroy (et al. Theme Atlas of Anatomy)

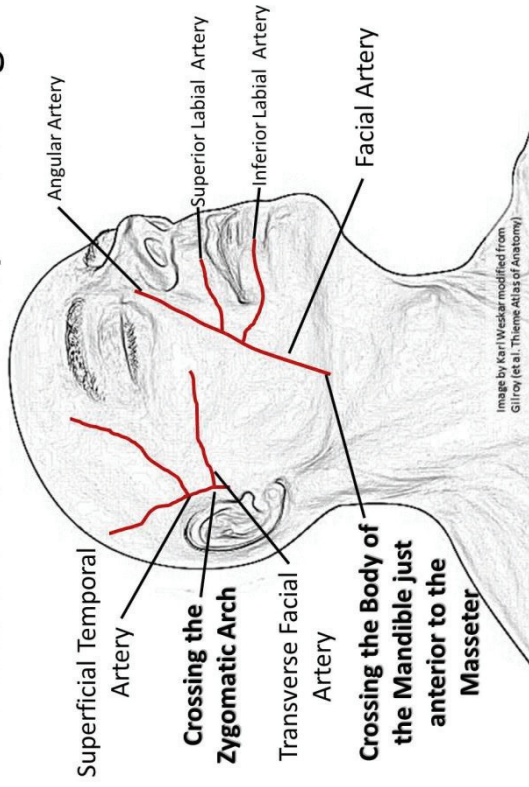
Larry Lovelace, DO, FACEP & Daniel O'Donoghue, PA-C, PhD

Laceration Zones

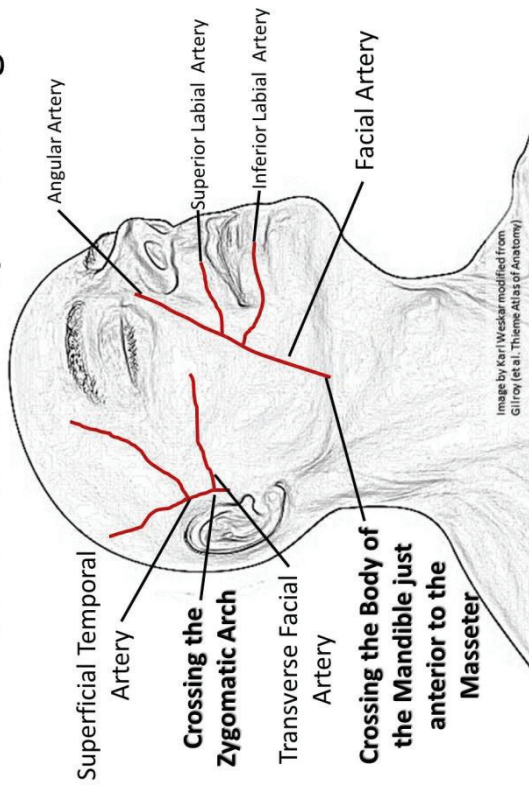
- Consider ending bout**
 - Careful evaluation of depth
 - One – tarsal plate, lacrimal sac**
 - Two - vermilion border**
 - Three – supraorbital / supratrochlear nerves
 - Four – nasal bridge, **FRACTURE**
 - Five – infraorbital nerve
 - Six – nasolabial fold with facial artery
 - Seven — superficial temporal artery, facial nerve (at the zygomatic bone)
 - Eight - facial artery at masseter**
 - Nine – mental nerve**
-
- Image by Karl Weskar modified from Gilroy (et al. Theme Atlas of Anatomy)

Larry Lovelace, DO, FACEP & Daniel O'Donoghue, PA-C, PhD

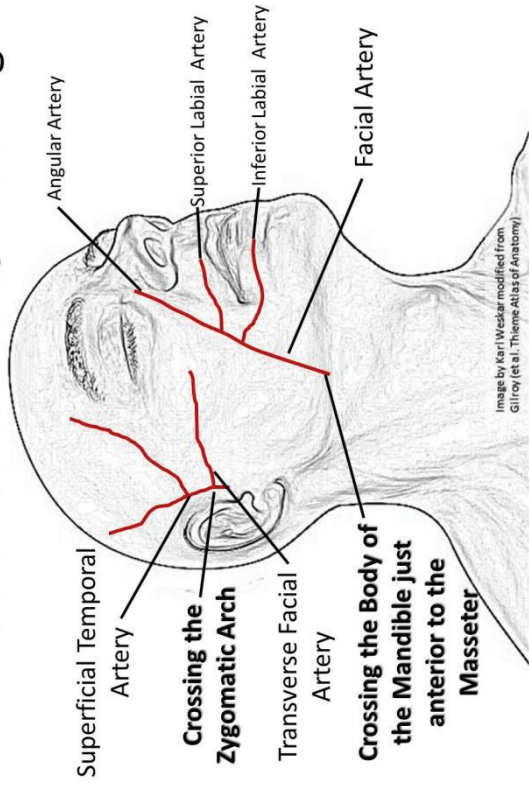
Pressure Points to Stop Bleeding



Pressure Points to Stop Bleeding



Pressure Points to Stop Bleeding



Pressure Points to Stop Bleeding

